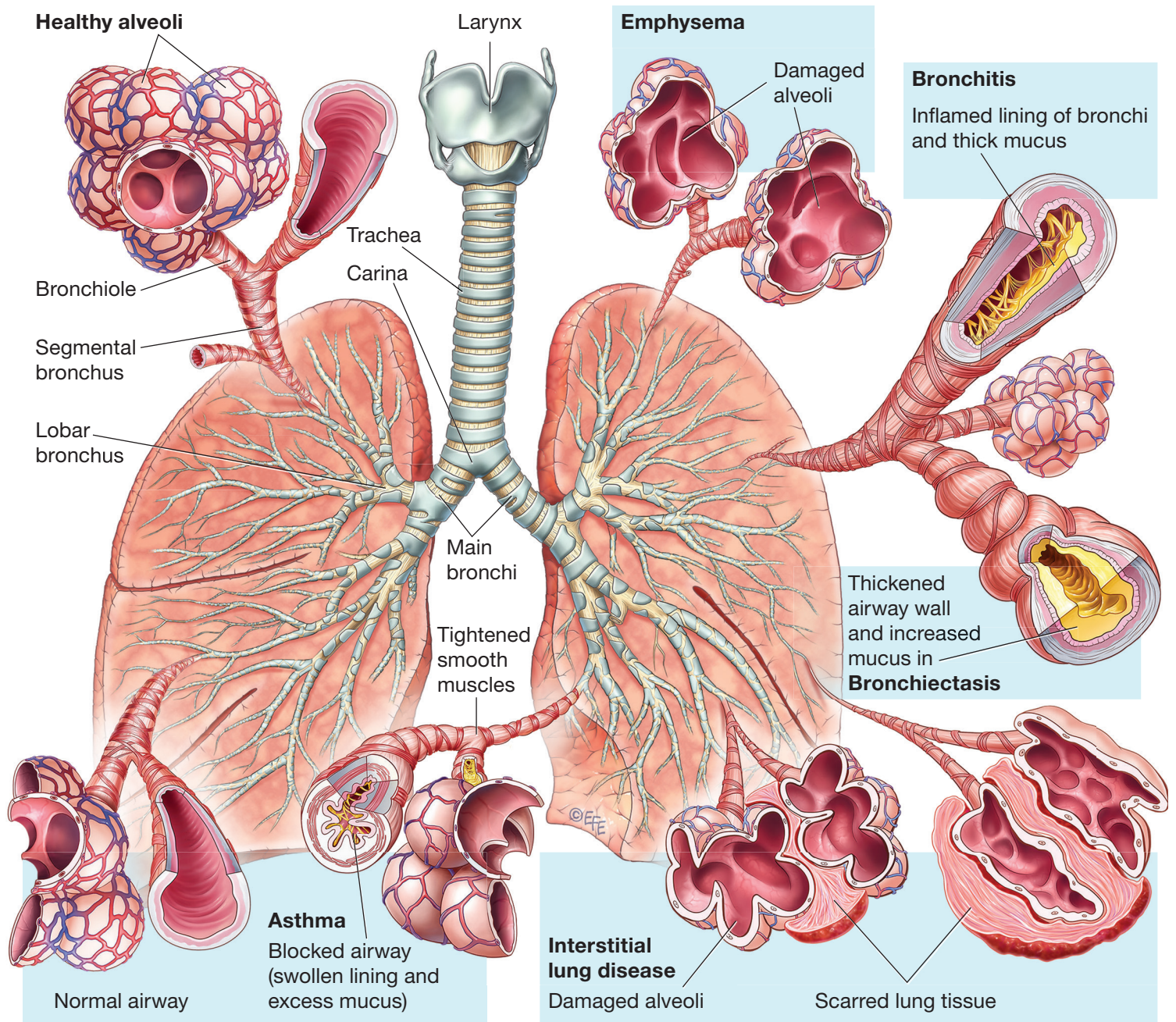
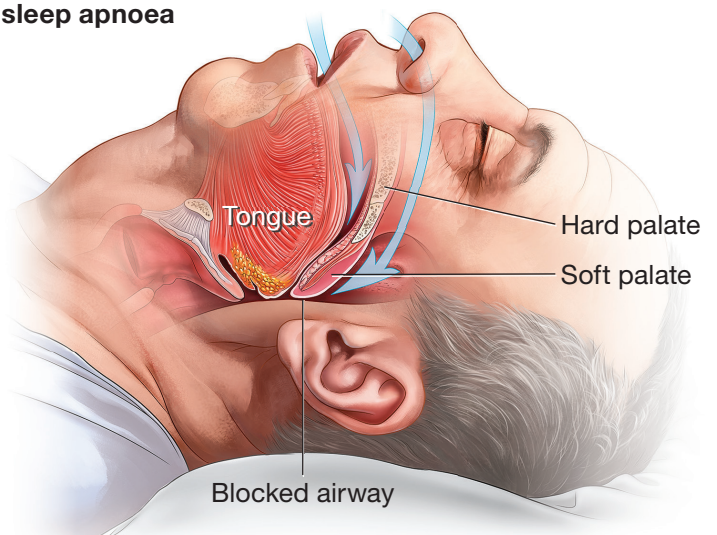
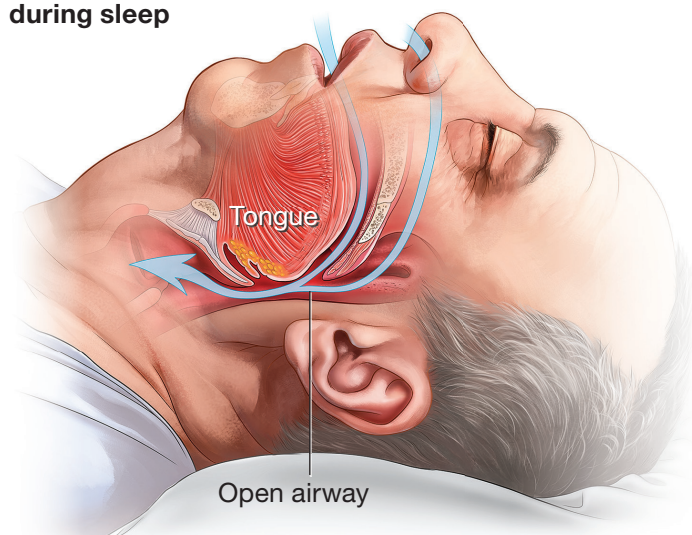


Anatomy of the Respiratory System

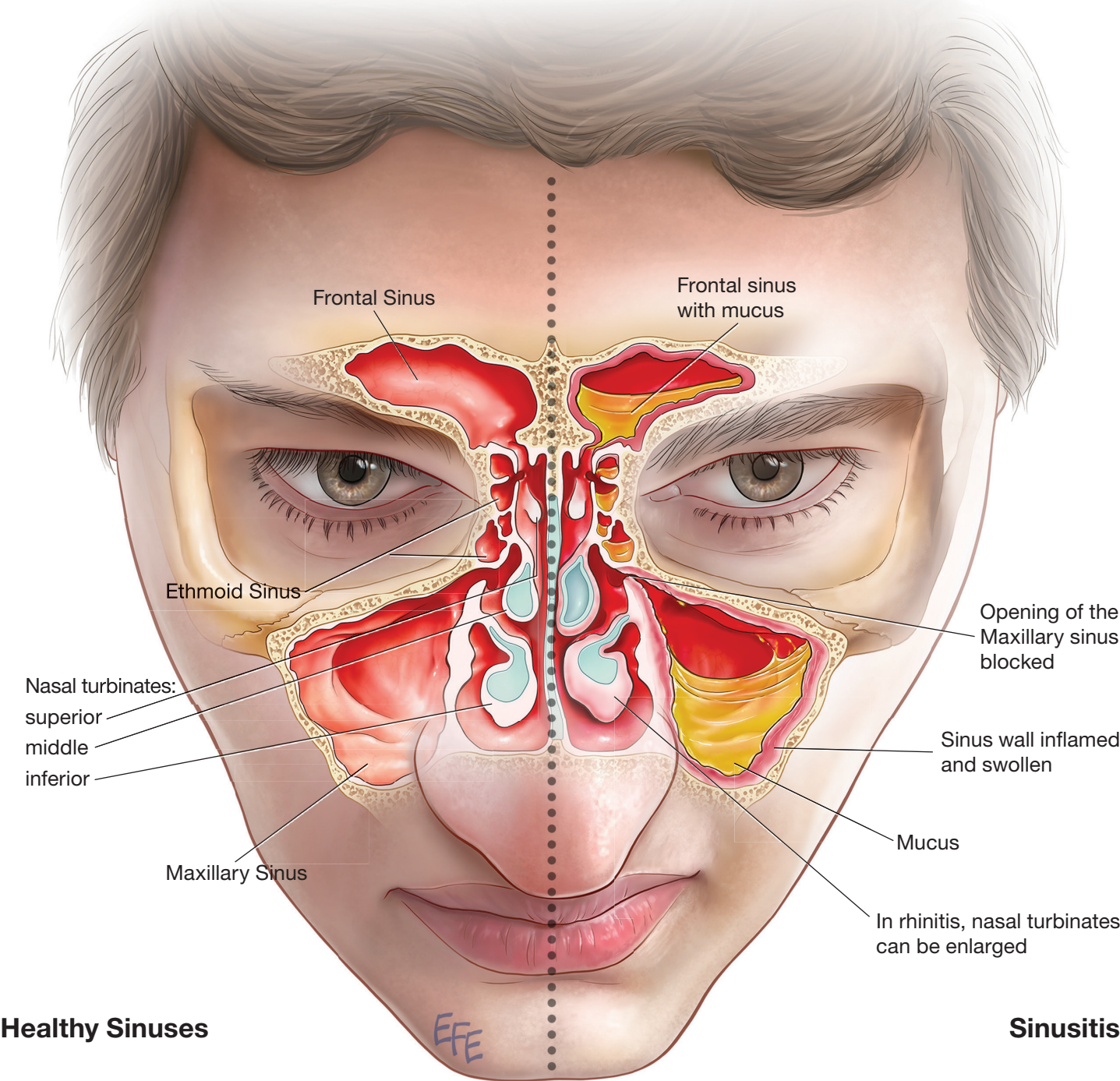


Normal breathing during sleep

Obstructive sleep apnoea



Anatomy of the Nose and Paranasal Sinuses



Patient's Name: _____ Date: _____

Clinician: _____

Notes: _____
